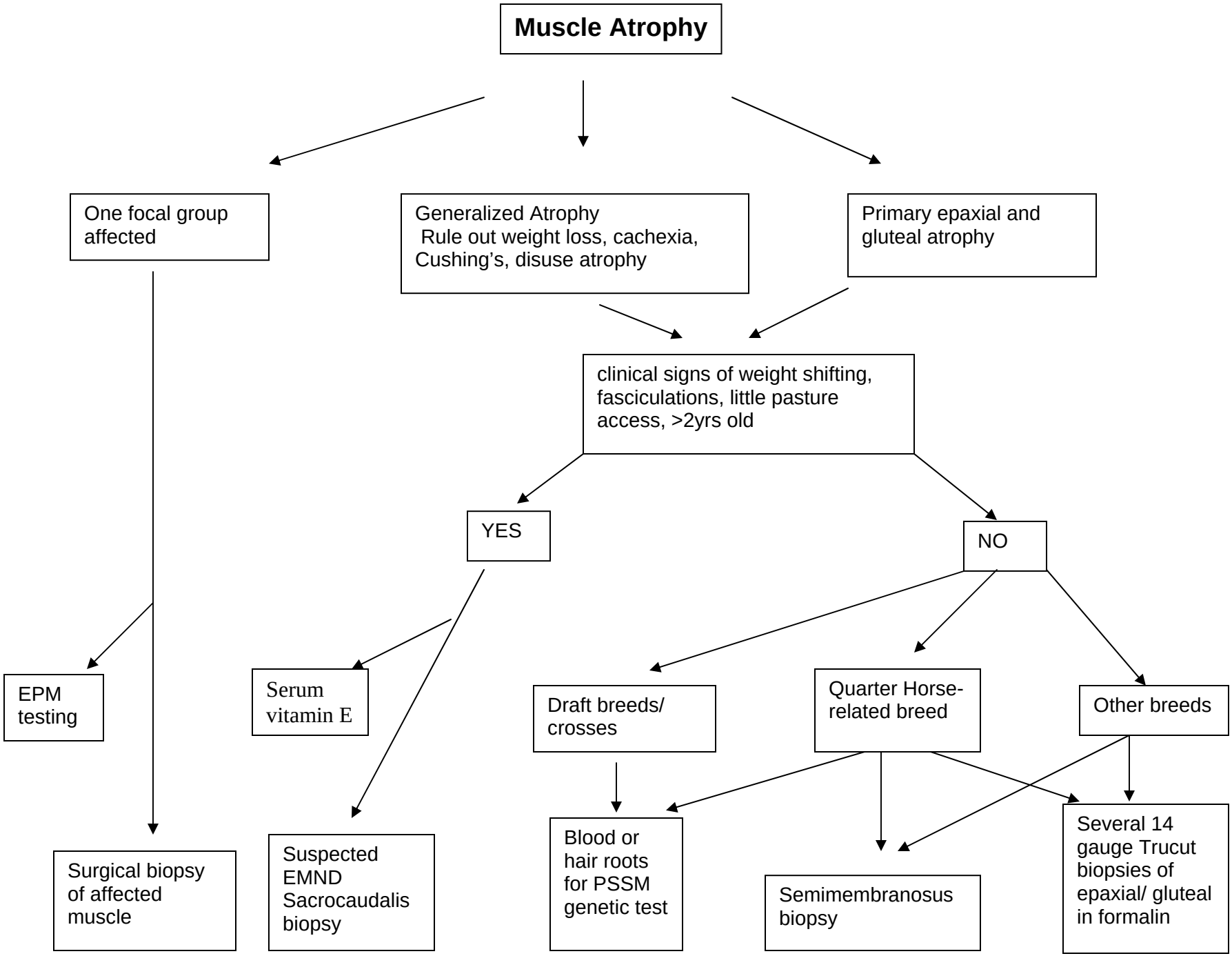
Muscle Atrophy
One focal group affected
Generalized Atrophy
Rule out weight loss, cachexia, Cushing's, disuse atrophy
Primary epaxial and gluteal atrophy
clinical signs of weight shifting, fasciculations, little pasture access, >2yrs old
YES
NO
EPM testing
Serum vitamin E
Draft breeds/ crosses
Quarter Horse-related breed
Other breeds
Surgical biopsy of affected muscle
Suspected EMND Sacrocaudalis biopsy
Blood or hair roots for PSSM genetic test
Semimembranosus biopsy
Several 14 gauge Trucut biopsies of epaxial/ gluteal in formalin